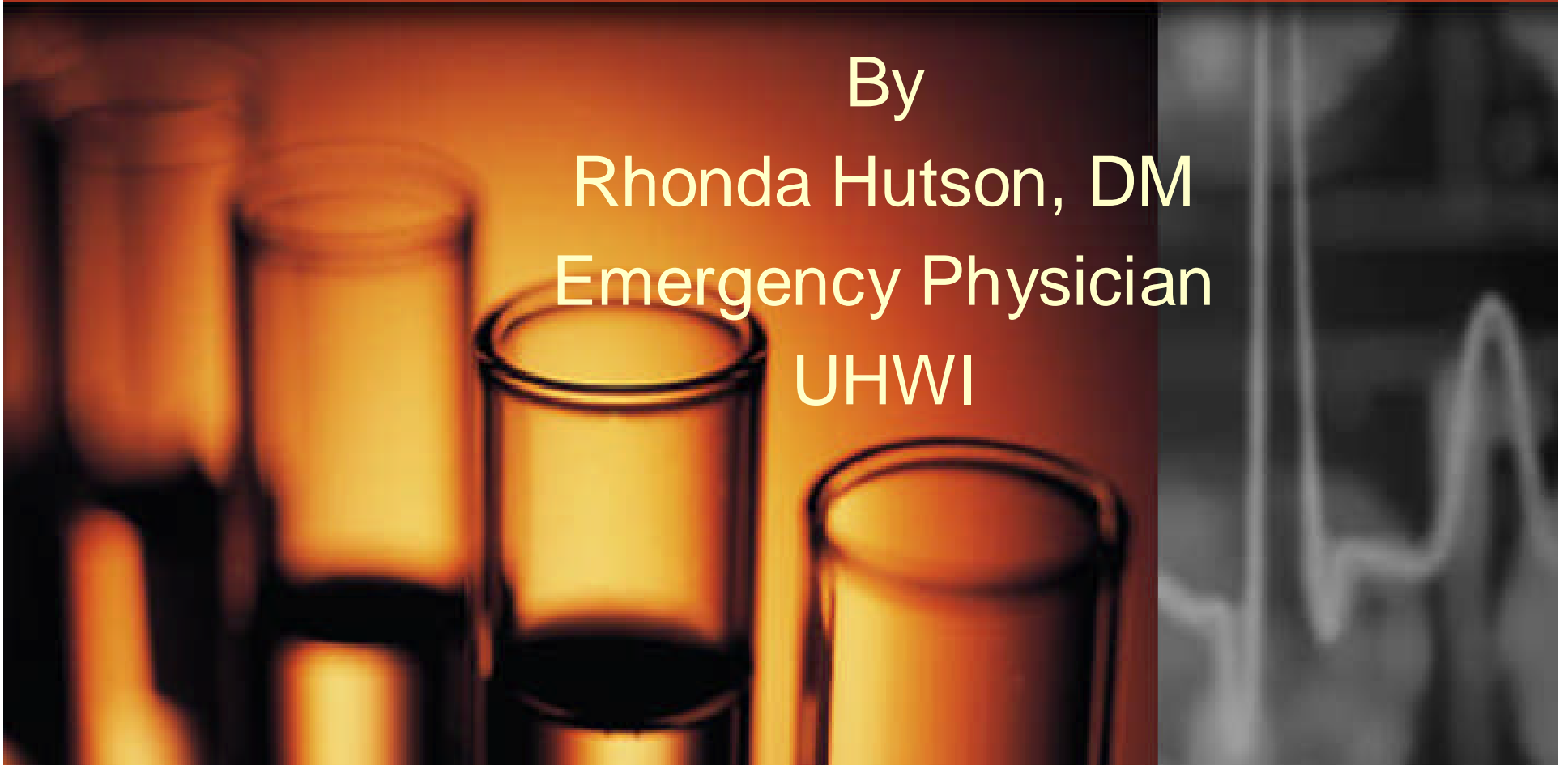


Case studies of poisoning at the University Hospital of the West Indies

By

Rhonda Hutson, DM
Emergency Physician

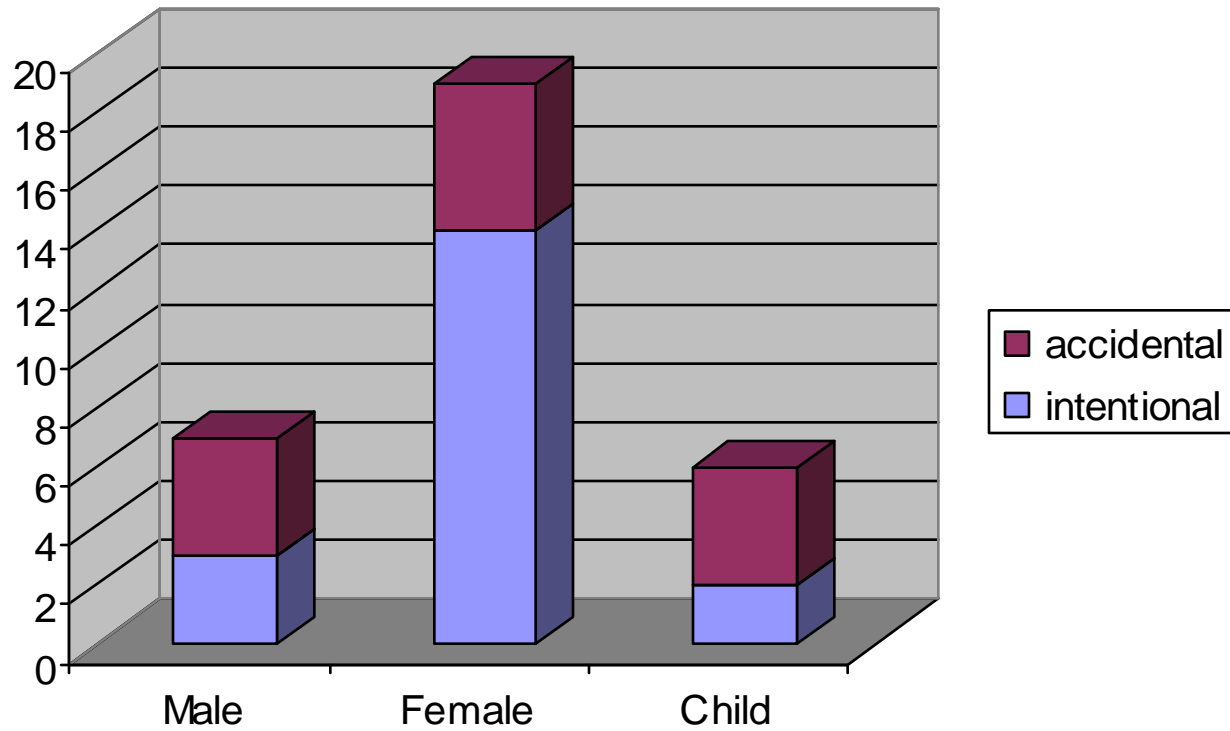
UHWI



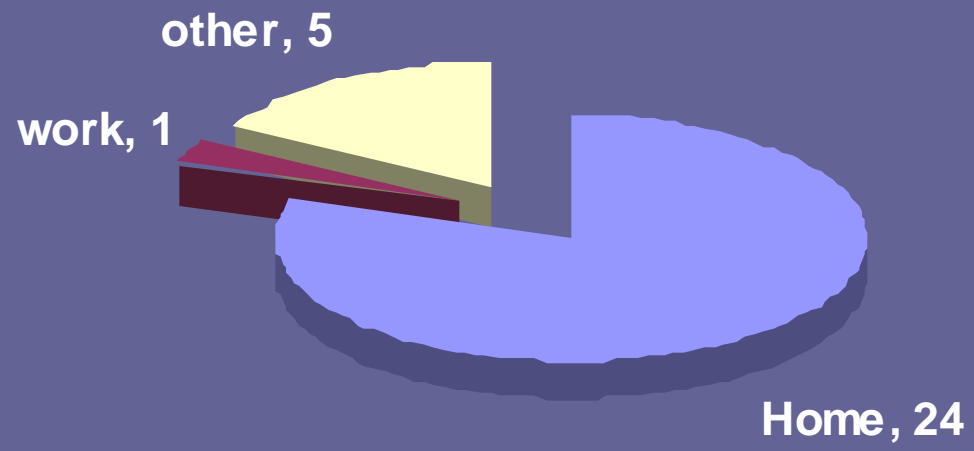
Poisoning data

- December 2005 and April 2006
- 31 cases recorded (1 discarded)
 - Males – 7
 - Females – 17
 - Children – 6
- 29 ER evaluations
- 1 call-in

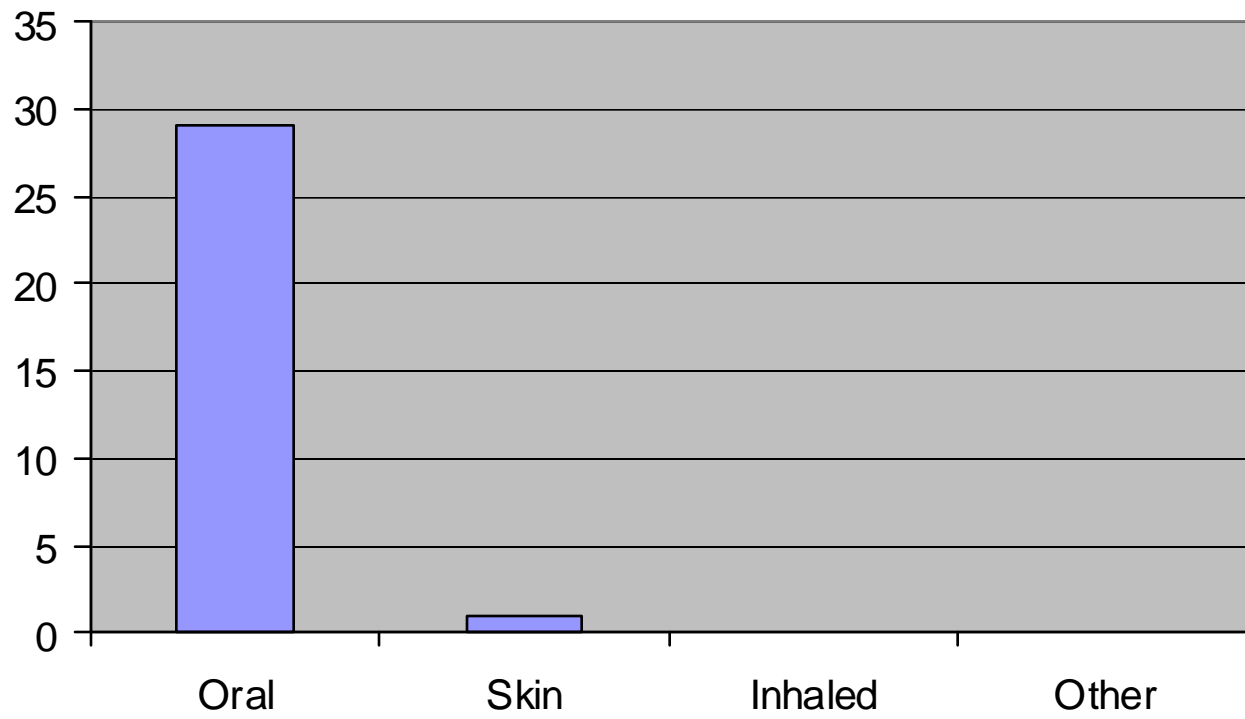
Intentional versus accidental poisoning



Location of Poisoning

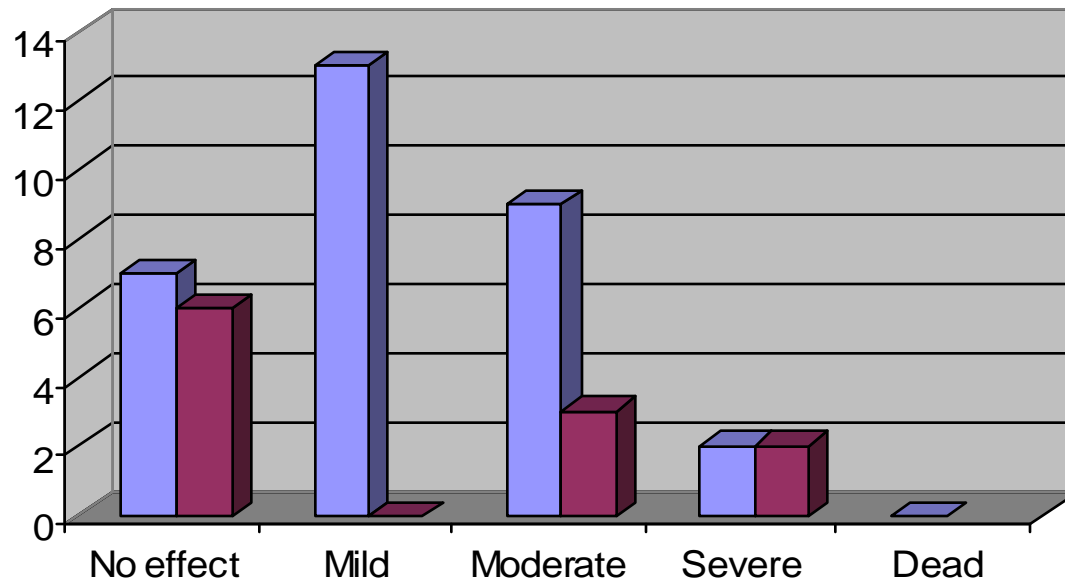


Route of Exposure



Clinical Presentation

■ Clinical features ■ Admissions





Agent	Number
Corrosive substance	1
Antihypertensive	5
Hair Product	1
Acetaminophen	3
Alcohol	3
Isopropyl alcohol	1
Ammonia	1
NSAID	5
Red Bull**	1
Powdery substance*	1
Benzodiazepine	2
Fluoxetine	1
OCPs	1
Aspirin	1
Bleach	3
Ganja	2
Paint thinner	1
Rat poison	1
Shellfish	1
Automotive paint	1

Co-ingestions

- Red bull + powdery substance – 1
- NSAID + OCP – 1
- NSAID+ Alcohol + antihypertensive – 1
- Acetaminophen + aspirin + caffeine - 1
- Fluoxetine + benzodiazepine - 1

Case 1

- 3/2/06, 4:35pm: TC, 26 years old
- HPC: overdosed on 20 Advil tablets
- Time of ingestion unknown
- Vomited twice; drowsy on way to hospital
- PMH: bladder carcinoma, metastatic bone disease, phaeochromocytoma, chemotherapy

Case 1

- Psyche. Hx: 5 previous suicide attempts
- O/E: drowsy, pink mucous membranes, anicteric, afebrile
- Vitals: T=36.2°F; PR 85 beats/min; RR 20 breaths/min; BP 95/53mmHg; O₂ Sat. 99%
- Cardiovascular, respiratory, and abdominal examination normal
- CNS: drowsiness

Case 1

- Activated charcoal via NGT
- Normal saline infusion (IV)
- 50mg ranitidine (IV)
- Blood studies: CBC, PT/PTT, U&E's, LFT's
- Assessed by psychiatric and internal medicine services
- Transferred to KPH

NSAID toxicity

- > 13 million Americans use them daily
- Inhibition of COX - blockade of prostaglandin production.
- *COX-1* - concentrated in platelets, vascular endothelial cells, gastric mucosal cells, and renal collecting tubules.
- *COX-2*- the inducible enzyme
 - expressed only in response to certain inflammatory stimuli

NSAID toxicity

- Completely absorbed from the upper small intestine
- Non-ionized in the stomach
 - diffuse readily across the bipolar layer lipid membrane of gastric-lining cells
- Ionised intracellularly (mucosal cells)
- Metabolism by oxidation and glucoronidation in liver
- Excreted in urine

NSAID toxicity

- Benign, rapidly reversible course
- Symptomatic overdose requires ingestion of at least 100 mg/kg
- Mild GI or CNS disturbance that resolves in 24 hours
- Reversible renal dysfunction - after massive acute overdose

NSAID toxicity

- Mild metabolic acidosis,
- Muscle fasciculations, mydriasis,
- Chills, diaphoresis, hyperventilation,
- Mildly elevated systolic blood pressure, hypotension,
- Asymptomatic bradycardia,
- Dyspnea, tinnitus, and rash.

NSAID toxicity

- The management of **NSAID** overdose is supportive
- Treat hypotension aggressively
- Pyrazolone and fenamate –
 - higher morbidity; managed more aggressively.

NSAID toxicity

- Children with ingestions of less than 100 mg/kg of ibuprofen - no medical evaluation.
- Ingestions > 300 mg/kg
 - GI decontamination, evaluation, and observation.
- Ingestion of 100 to 300 mg/kg
 - children need treatment only if symptoms develop.
- Adults who deliberately overdose on NSAIDs
 - should undergo a period of observation in the ED
 - psychiatric evaluation.

Case 2

- CG, female, 25 years old
- Mother could not arouse her from sleep
- Empty container of Lexotan tablets at bed: 17 missing (3mg tabs.)
- Prescribed Lexotan for depression
- Brought to ER about 1 hour after discovery

Case 2

- PMH: asthma
- O/E: GE satisfactory
- Vitals: T=97.6°F; PR 62/min.; RR 24/min; BP 120/66mmHg; O₂ sat. 98%, RBG 3.4mmol/L
- Respiratory, cardiovascular, and abdominal exams normal
- CNS: very drowsy; GCS 13/15; oriented to person only

Case 2

- Gastric lavage, activated charcoal
- Oxygen via nasal canula
- IV fluids
- Flumazenil 0.5mg IV stat
- Blood studies: all normal
- Pregnancy test negative
- Admitted to the medical ward, discharged 1 day later

Benzodiazepine overdose

- Most common prescription drug used in drug-assisted suicide in USA
- Effects: sedative, hypnotic, anxiolytic and anticonvulsant
- Enhances inhibitory action of GABA
- Rapidly absorbed and readily distributed
- Highly lipophilic – easy penetration of BBB

Benzodiazepine overdose

- Metabolised in the liver
- Clinical features (overdose):
 - CNS depression
 - Respiratory depression (large doses)
 - Ataxia common in children
- Testing: urine- oxazepam glucoronide
 - (Clonazepam, lorazepam, midazolam alprazolam)

Benzodiazepine overdose and flumazenil

- Flumazenil, a nonspecific competitive antagonist of the benzodiazepine receptor
- It can quickly confirm a clinical diagnosis
- Reversal of conscious sedation

Benzodiazepine overdose and flumazenil

- Weinbroum et al, Crit Care Med 1996; 24(2) :
- 110 patients: 31 in RDB (1mg flumazenil or normal saline)
 - 14/17 FTPs awoke
 - 1/14 NSP
 - Flumazenil is a valuable diagnostic tool;
 - effective in preventing occurrence
 - Respiratory insufficiency is reversed

Benzodiazepine overdose and flumazenil

- NICE guidelines
<http://www.nice.org.uk/pdf/CG016NICEguideline.pdf>.
- The administration of flumazenil should be considered in patients presenting with an overdose of benzodiazepines.
- Should not be used if the patient is benzodiazepine dependent

Benzodiazepine overdose and flumazenil

- The National Poisons Information Service (Toxbase)

<http://www.spib.acl.co.uk/toxbaseindex.htm>.

- Flumazenil should only rarely be required in benzodiazepine overdose

Benzodiazepine overdose and flumazenil

- Indications
 - Isolated benzodiazepine overdose in non-habituated user (e.g., accidental pediatric exposure)
 - Reversal of conscious sedation

Benzodiazepine overdose and flumazenil

-

Absolute Contraindications

- Known or suspected coingestant that lowers seizure threshold
- Tricyclic antidepressants, cocaine, lithium, methylxanthines, INH, propoxyphene, MAO
- Patient taking benzodiazepine for control of a potentially life-threatening condition (e.g., seizures)
- Concurrent sedative-hypnotic withdrawal

Case 3

- 6 y.o male, OB
- PC: drank ammonia liquid, 6 hrs earlier;
 - burning of the mouth, throat and chest
 - decreased oral intake
 - Wet cough
 - Mouth washed with water
 - No vomiting, abdominal pain, stridor

Case 3

- PMH: asthma
- O/E: respiratory distress, acyanotic, not drooling
- Vitals: T=101.°F; PR142/min. RR 32/min;O₂ sat. 96%
- RS: Clear lung fields
- CVS,CNS, Abd – normal
- Mouth: erosion on tongue and posterior oro-pharynx; hyperaemia of tonsils

Case 3

- IV fluids
- Blood studies: WBC 13.6
- CXR: normal
- ENT service:
 - Hydrocortisone 50mg IV
 - Rigid oesophagoscopy: 'slough' at base of tongue, posterior pharyngeal wall hyperaemia
 - Steroids continued
 - Discharged 1 day later on steroids and antibiotics
 - Clinic F/U: doing well

Caustic ingestions and steroids

- Corticosteroid therapy remains controversial
- Advocated to potentially prevent stricture formation
- Circumferential second-degree burn injuries of the esophagus
- Prednisolone
 - 2 mg/kg/day in children
 - 40 mg tid in adults for 14 to 21 days

Caustic ingestions and steroids

- Prophylaxis with antibiotics that treat oral pathogens and anaerobic bacteria (e.g., ampicillin or clindamycin) should be initiated *only if corticosteroid therapy is utilized*

Thank you

